

# Some modifications to the Step-back technique in root canal preparation

Paul S. McCabe B.D.S., N.U.I., MSc.

## INTRODUCTION

Schilder<sup>1</sup> defined the general objectives of root canal preparation: Root canals must be cleaned of their organic remnants and shaped to receive a three dimensional filling. Canal cleaning and shaping is generally accomplished with intracanal instruments, however these alone are not able to remove all the tissue remnants and debris from the canal system, so thorough flushing with intracanal irrigants must go hand in hand with the instrumentation of the canal system.<sup>2</sup> In theory, the files loosen and disrupt materials within the canal system and remove dentine from the walls as shavings; this whole sludge is then flushed out with an irrigant. The most popular and advocated irrigant is sodium hypochlorite, in various concentrations<sup>3,4</sup>.

This article will deal with only one aspect of this so-called chemo-mechanical debridement, that of instrumentation. Various instrumentation techniques have emerged over time<sup>1,5,6</sup>. One technique, however, has become the yardstick to which all other techniques are compared. This technique is known as the step-back or serial technique and will be discussed in this article.

## SERIAL/STEPBACK TECHNIQUE

The step-back technique was first described by Clem<sup>7</sup> and became popularized when a series of research articles indicated its superiority over the standardized technique described by Ingle<sup>5</sup>. It is currently the most widely taught endodontic technique<sup>8</sup>.

Tidmarsh<sup>9</sup> described the features of the ideal root canal preparation: firstly, minimal enlargement at the apical end of the canal; secondly, the provision of an apical stop; thirdly, the creation of an even, progressive taper that follows the natural curvature of the root. Schilder<sup>1</sup> advocated a similar preparation; a continuously shaped conical form from apex to the crown. This was accomplished by serial filing and reaming and recapitulation. Serial filing and reaming denote that instruments of greater width are used short of the apex, in series. Recapitulation refers to the reintroduction or reapplication of instruments previously used throughout the cleaning and shaping process. In other words, instead of taking all instruments to the same length, the clinician uses the instruments only where they can safely fit, with only the smallest files reaching the canal terminus. Larger instruments are stiffer and more aggressive than smaller ones, thus increasing the chances of diverting the original canal path. (see FIG.1)

The apical stop is an intentional ledge as such and is generally prepared with a reaming type action<sup>8,10</sup>. The remainder of the step-back portion of the preparation is by peripheral filing<sup>8,10</sup>.

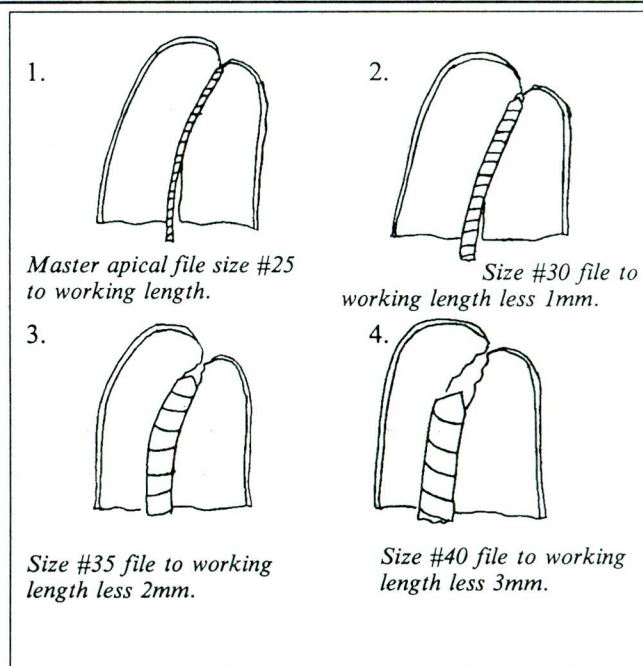


Figure 1. The Step-back technique

The term step-back refers not to the creation of a series of steps or ledges in the canal, but rather to the stepping back farther from the apical preparation with each progressively larger instrument.

Thus the objectives of the step-back technique are to keep the apical portion of the preparation as small as possible with an increasing taper throughout the remainder of the canal and that the final apical preparation should be in the same position as the original canal.

This tapered shaped preparation provides important advantages in:

1. Irrigation efficiency<sup>10</sup>. This preparation allows the insertion of the irrigation needle deep into the canal system, thus maximising the flushing effect.

2. Minimal apical opening<sup>9</sup>. This is essentially conservative of dentine and is consequently less prone to result in root perforation or opening of the apical foramen.

3. Obturation. Gutta percha has become the standard to which all other obturating materials are compared. Lateral condensation of gutta percha is the most commonly advocated method of obturation<sup>8</sup>. Allison *et al.*<sup>11</sup> demonstrated that the quality of the apical seal when using a lateral condensation technique was related directly to the method of preparation and that a tapered preparation, such as that exhibited by the step-back technique, allowed the insertion of a canal spreader to within 1mm of the prepared length and had significantly less apical microleakage than a non-tapered preparation.

However, there are three aspects of root canal morphology that merit specific attention during root canal preparation.

### 1. Canal Access.

As the understanding and knowledge increases about the shortcomings of the different canal preparation techniques, increasing emphasis is being placed on the need for careful tactile control of the instruments which is only possible if there is no impediment to the positioning and cutting action of the instrument at whatever level it is operating at within the canal. It follows therefore that the shape of the coronal cavity through which the canal is entered must ensure unimpeded straight line access to each canal. (See FIG. 2)

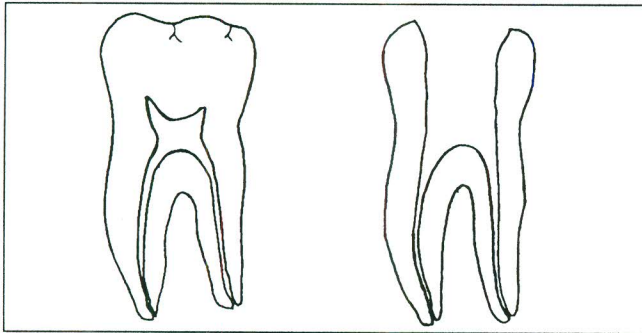


Fig. 2. Straight line access

Walton and Torabinejad<sup>12</sup> state that the straighter the approach of the file in the canal the less the probability of a preparation error in the apical region. Recently the preparation of the coronal portion of the canal prior to the apical portion has received a considerable amount of support<sup>14,15</sup>. The rationale for this being that it would eliminate the binding of instruments in the coronal portion of the canal which would allow controlled apical cleaning and shaping. This will be dealt with in more detail later.

### 2. Canal Curvature

According to Buchanan<sup>15</sup>, all root canals have some curvature. The problems associated with the preparation of curved canals have received much publication<sup>16,17,18,19,20</sup>. Weine *et al*<sup>21</sup>, using the step-back technique, noticed some undesirable characteristics during the preparations of curved canals. These preparations were hour-glass rather than funnel shaped which would make canal obturation difficult. Various treatment modalities have been suggested to overcome this problem.

Weine *et al*<sup>21</sup> recommended the removal of flutes from the outer portion of the enlarging instrument near the apex in order to prevent this aspect of the instrument cutting into the tooth and, in conjunction with this, to use the instrument with a rasping type action rather than a reaming type action. However, neither of these proposals gained widespread acceptance.

Walton and Torabinejad<sup>8</sup> recommend limiting the size of the apical preparation in curved canals. It must be remembered that large instruments undergo a greater restoring force to return them to their original straight position, thus accounting for their straightening effect seen during root canal preparation. Thus it appears that in order to overcome the difficulties associated with

curved canals, we have to accept a smaller sized preparation than would suffice for a straight canal. Morgan and Montgomery<sup>22</sup> are of the same opinion. In a study on curved canal preparations, ElDeeb and Borass<sup>23</sup> found that regardless of the file type canal zipping increased significantly with increases in the file size, especially from #30 to #35, which led them to conclude that in curved canals, apical preparation should be limited to size #25 or size #30.

### 3. Relationship of the Canal to the External Surface of the Root

Relatively straight roots, that are nearly round in cross-section, have the root canal placed centrally but this is by no means the case with flattened and curved roots where the canal may be much closer to one aspect of the root than the other. The removal of dentine from such an area may result in a stripping perforation. Abou-Rass *et al*<sup>24</sup> proposed the anticurvature method of filing which directed the preparation into the bulkier parts of the root canal walls and away from the thinner portions where preparation could result in perforation. This method of preparation received fairly widespread support. However, Lim and Stock<sup>25</sup> demonstrated that although the anticurvature filing significantly reduced the risk of perforation through the furcal surface of the root, canals prepared by this method were more irregular in cross section when compared with those prepared by the step-back technique: this, they postulated, would lead to greater difficulty with obturation.

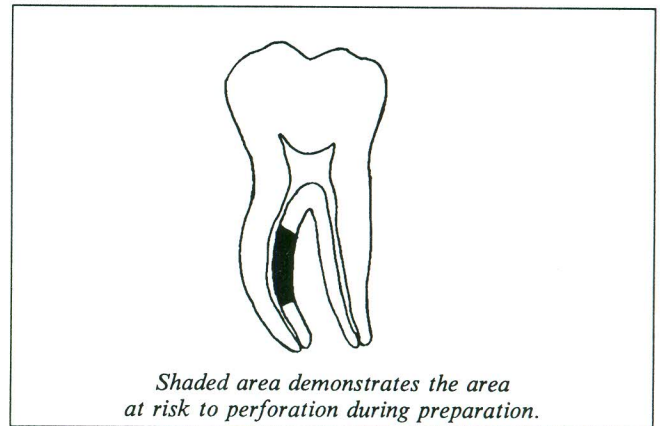


Fig. 3. Anti-curvature Filing

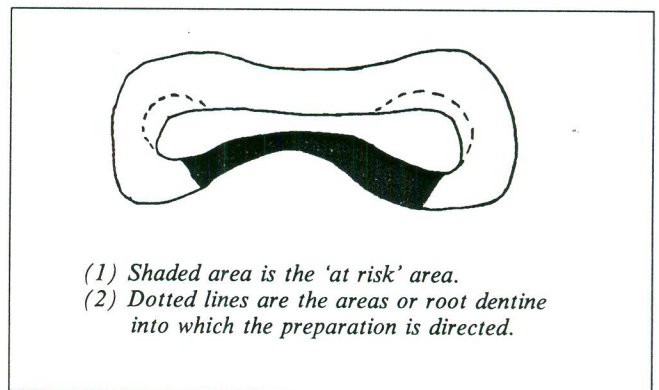


Fig. 4. Anti-curvature Filing  
Cross section of mesial root of lower first molar

## EARLY CANAL FLARING

As a result of studies carried out by Leeb<sup>13</sup> increasing emphasis was placed on early enlargement of the canal orifice and the coronal third of the canal. This early intervention was seen to eliminate canal interferences cervical to the apical constriction. This led to the development of a series of early canal flaring techniques.

Goerig, *et al*<sup>26</sup> described a step-down technique of radicular access. Hand instrumentation was used to eliminate gross dentinal interferences and pulp tissue down to the approximate junction of the middle and apical thirds of the root. This enlarges the canal system sufficiently for the unhindered placement of the Gates-Glidden burs, thus creating a flared preparation in the coronal half to two-thirds of the canal, resulting in a straighter access to the apical portion of the canal, which is then prepared using the step-back technique. This early canal flaring has gained considerable acceptance<sup>22</sup>. Fava<sup>27</sup> devised an early coronal flaring technique known as the double flared technique, where the cervical and middle thirds of the root canal are instrumented by hand, before stepping down to instrument the apical third, which is also prepared in the conventional step-back fashion. This early flaring was also seen to have other beneficial effects.

1. As a result of studies carried out by Shovelton<sup>28</sup>, who studied the distribution of bacteria within nonvital teeth, it may be concluded that any method of instrumentation which would remove all the contaminants situated at higher levels in the root canal prior to apical instrumentation would tend to reduce the amount of contaminants available to be forced apically.

2. Hession<sup>29</sup> postulated that early canal flaring would lessen the potential for a positive apically directed hydrostatic pressure by the establishment of an adequate coronal escapeway. This would therefore reduce the amount of debris extruded. This, in fact, has been validated by studies carried out on debris extrusion during endodontic manipulation using an early flaring technique<sup>30,31</sup>.

Thus the advantages of early canal flaring are:

a. The bulk of the pulp tissue, debris, and micro-organisms are removed before apical instrumentation, greatly reducing the number of contaminants that could be extruded during apical instrumentation. The extrusion of debris during root canal manipulation is often responsible for post treatment symptoms.

b. The early enlargement of the coronal and mid root sections of the canal allows a deeper penetration of irrigating solutions enhancing their effects.

c. The working length is less likely to change during subsequent apical instrumentation because the canal curvature has been reduced before establishing the definitive working length<sup>32</sup>.

d. Creating the apical preparation early in the shaping procedure may potentiate unintentional apical damage and overenlargement. This area of the root canal system is by far the most complex part of the system<sup>33</sup> and the area where the clinician has least control. Early flaring techniques remove all hindrances in the canal system prior to apical instrumentation, thus allowing better apical control.

e. It is possible to incorporate some degree of anti-curvature filling in the early flaring techniques by

directing the files or Gates-Glidden burs into the bulkier aspects of the roots as discussed above.

Thus it would appear from the literature that an early flaring technique has definite advantages over the step-back technique.

## SUMMARY

Step-back technique is the standard to which all other root treatment techniques are judged. The complexity of root canal systems dictates that modifications to a particular technique are inevitable. Unimpeded straight line access, early canal flaring with or without anti-curvature filing where indicated and limitation of the size of apical preparation in curved canals, offer the clinician flexibility while using the step-back technique. Although these modifications have not stood the test of time they are based on sound principles and merit serious consideration.

## REFERENCES:

1. Schilder H. *Cleaning and shaping of the root canal*. Dent. Clin. North Amer. 1974;18:269.
2. Rubin B. et al. *The effect of instrumentation and flusing of freshly extracted teeth in endodontic therapy: a scanning electron microscope study*. J. Endod 1977; 3:194.
3. Crabb H. *The cleaning of root canals*. Int. Endod J. 1982;18:35.
4. Holloway N. *Results of a survey of endodontic irrigants and medicaments*. MSc Thesis, 1984 Ann Arbor, Michigan.
5. Ingle J. *A standardised endodontic technique utilising newly designed instruments and filling materials*. Oral Surg. 1971;14:83.
6. Johnson T., Zelikow R. *Ultrasonic endodontic: a clinical review*. J. Amer. Dent. Assoc. 1987;114:655.
7. Clem W. *Endodontics: the adolescent patient*. Dent. Clin. North Amer. 1969;13:483.
8. Walton R., Torabinejad M. *Cleaning and shaping, in Principles and Practice of Endodontics* (Editor D. Pedersen); 1st edition; 1989b: 195-222. W.B. Saunders.
9. Tidmarsh B. *Preparation of the root canal*. Int. endod. 1982;15:53.
10. Chow T. *Mechanical effectiveness of root canal irrigation*. J. Endod. 1983;9:475.
11. Allison D., Weber C., Walton R. *The influence of the method of root canal preparation on the quality of apical and coronal obturation*. J. Endod. 1979;5:298.
12. Walton R. Torabinejad M. *Access preparation and length determination; in Principles and Practice of Endodontics* (Editor D. Pedersen), 1st edition, 1989;173-193. W.B. Saunders.
13. Leeb J. *Canal orifice enlargement as related to biomechanical preparations*. J. endod. 1983;9:463.
14. Abou-Rass M., Jastrab R. *The use of rotary instruments as auxiliary aids to root canal preparation in molars*. J. Endod. 1982;8:78.
15. Buchanan, L. *Cleaning and shaping the root canal system; in Pathways to the Pulp* (Editors S. Cohen and R. Burns), 5th edition. 166-192. C.V. Mosby.
16. Mullaney, T. *Instrumentation of finely curved canals*. Dent. Clin. North Amer. 1979;23:575.
17. El Deeb M.E., Borass J.C., Southard L.Z. *Instrumentation of curved canals using modified tipped instruments: a comparison study*. J. Endod. 1988;14:59.
18. Abou-Rass M., Jastrab R. *The use of rotary instruments as auxiliary aids to root canal preparation in molars*. J. Endod.