

# Amalgam crown restorations for posterior endodontically treated teeth

P. S. McCabe B.D.S., M.Sc.\*

\*Oranmore, Co. Galway

## INTRODUCTION

The restoration of the posterior endodontically treated tooth represents an everyday challenge to the restorative dentist. While some teeth are largely intact others are badly mutilated, with little or no sound supragingival tooth tissue remaining. The restorative challenge is to restore form and function to all endodontically treated teeth so that they may continue to serve successfully for many years. Cast restorations are the usual technique chosen for such restorations: this article will review the amalgam crown as a possible definitive restoration for the endodontically treated posterior tooth.

## REVIEW

The structural strength of the natural crown of a tooth is dependent on the quantity and intrinsic strength of the dentine and the integrity of the anatomic form. In the endodontically treated tooth the integrity of the anatomic crown is disrupted by coronal access and canal preparation techniques. This removal of tooth substance results in decreased strength of the tooth. In addition, the intrinsic dentine strength may be adversely affected by the absence of the pulp which results in a decreased moisture content of the dentine '1'. It has been postulated that such a loss of moisture leads to a very brittle tooth '2'. Therefore, as a result of a decreased amount of dentine, disruption of anatomic form, and a possible loss of intrinsic strength, endodontically-treated teeth have an increased susceptibility to horizontal and vertical fracture '3'. Such fractures may or may not be restorable. The traditional approach has been to place a cast restoration after the completion of endodontic therapy '4, 5, 6'. The casting serves to protect the remaining tooth from further destruction by preventing cuspal fracture while restoring proper contours, anatomic form and function. Although cast restorations are superior to large complex amalgam restorations '7' the amalgam restoration has a lot of advantages. These include:

1. Amalgam crowns are less expensive.
2. Less chairside time.
3. Only one appointment is required.
4. Temporisation is eliminated.
5. Dental laboratory is eliminated.
6. Laboratory personnel are not exposed to patients blood/saliva.
7. Dentist has complete control over all steps of the procedure.
8. If root canal therapy failure occurs amalgam crown may be removed with relative ease.
9. As a transitional restoration awaiting conversion to a cast restoration.

An amalgam crown may also be placed on a tooth that has an uncertain prognosis for either endodontic or periodontic reasons.

There can be no doubt about the longevity of amalgam restorations, particularly those restorations using the high copper alloys. One clinical study '8' has shown a 25% failure rate after 15.7 years, others '9, 10' have estimated the fifty percent survival of the high copper alloys to be 14 years.

Sorensen and Martinoff, '11', in a study of 1,273 endodontically treated teeth, found that coronal coverage significantly improved the clinical success rate of endodontically treated posterior teeth. They also noted that the use of a post to provide intracoronal reinforcement did not improve the success rate. They concluded that posts, although useful for retaining crown cores in certain cases, did not favourably affect the posterior tooth's ability to resist root fracture and so served no reinforcement value. This well quoted study stresses the need for cuspal protection on all endodontically treated posterior teeth. Cuspal protection may be incorporated in the amalgam crown.

Liberman et al. '12' investigated the effect of occlusal forces on amalgam overlay restorations and cast gold onlay restorations. They demonstrated that amalgam (non gamma 2) restorations were of sufficient strength to withstand occlusal forces and so was a suitable material for restoring endodontically overlay restoration was a successful restoration for the posterior endodontically treated tooth in the short term.

Brown et al. '14' and Starr '15', both advocated the use of the amalgam crown as the definitive restoration for the endodontically treated tooth.

The retention of complex amalgam restorations is a difficult task. Various methods supplementing the retention of complex amalgam restorations have been described in the literature '16, 17, 18', these include the placement of retentive pins, boxes, grooves and slots. More recently, the use of amalgam bonding to tooth substance to supplement retention in complex restorations has been described '19'. However, in the case of the endodontically treated tooth this matter is somewhat simplified because the pulp chamber and the first 2-4 mm of the root canal systems may be used for retention purposes. These supplementary methods of retention may also be used in the restoration of the posterior endodontically treated tooth when required.

Nayyar et al, '20' have described a technique for an amalgam dowel and core, this technique is largely based on their technique. However, Nayyar et al. '20' believe that the use of an amalgam crown to be a compromise because optimum axial contours, proper contacts, and optimum occlusion would best be achieved on a cast restoration.

Amalgam has been advocated as a material suitable for cores in pulpless teeth '20, 21' and so the amalgam crown can in time be prepared and serve as the dowel and core for a cast crown.

## PROCEDURE

It is essential that the size and width of the remaining pulp



chamber should be of sufficient width and depth to allow the placement of an adequate bulk of amalgam. It is recommended that a non gamma 2 amalgam be used.

1. It is usually most convenient to complete the amalgam crown at the conclusion of the obturation appointment. At this stage the tooth is already isolated with rubber dam and the internal anatomy of the tooth is fresh in the dentists mind. Therefore the placement and removal of a temporary filling is avoided and an extra appointment is also avoided.
2. Using the post obturation radiograph the size, configuration and direction of the canals can be re-evaluated. Then using a hot instrument such as a root canal plugger remove the gutta percha to a depth of 2-4 mm from each canal.

Occasionally it may be necessary to increase the diameter of the canals with Gates Glidden burs so that there is a sufficient bulk of amalgam.

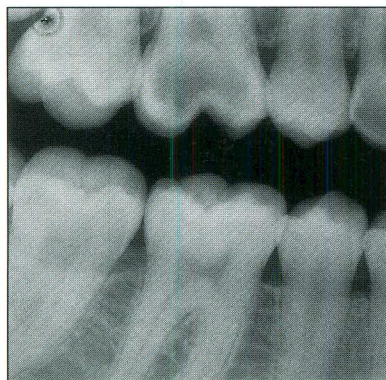
3. Remove all unsupported enamel. The basic principals of a conventional amalgam restoration should still apply regarding resistance and outline form. Retention will be provided by the natural undercuts of the pulp chamber and divergent canals. The need for cuspal protection should be assessed.
4. Select a suitable matrix band which should be wedged where possible to avoid overhangs.
5. Condense the amalgam into the coronal aspect of the canals and any other supplementary retention areas first. It is essential that the plugger can actually fit into these areas to ensure a thorough condensation. The pulp chamber and coronal aspects of the cavity are then condensed conventionally.
6. Remove the matrix band and carve the amalgam into an anatomic form.
7. Check the occlusion and ensure there is an even centric contact in the maximum intercuspal position and remove all contact in lateral excursions where present.
8. Review in one week for assessment.

## DISCUSSION

The restoration of the posterior endodontically treated tooth which is largely destroyed by caries and further weakened by endodontic therapy, offers a challenge to every dentist. This article demonstrates a procedure which, although is not the ideal restoration, has its advantages. It is based on sound principals. Amalgam has been shown to be sufficiently strong to be used in overlay restorations '9, 10, 11, 12' and should be part of every dentist's armamentarium.

## CASE REPORT

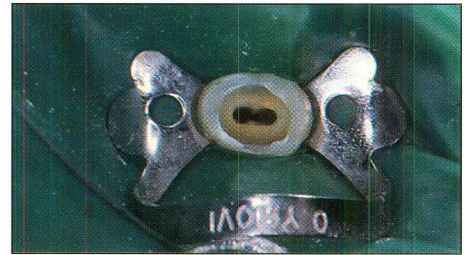
*Figure 1:* A young lady with two perfectly intact dental arches presents in pain at the surgery. A diagnosis of chronic irreversible pulpitis was made with involvement of both 64/. The treatment options were discussed this already involved the restorative implications and the need for cuspal protection. Financially it was not possible for the patient to have two root canal treatments followed by two cast porcelain to precious metal crowns at this moment in time. Root canal treatments were agreed with the placement of two amalgam crowns which would act as cores



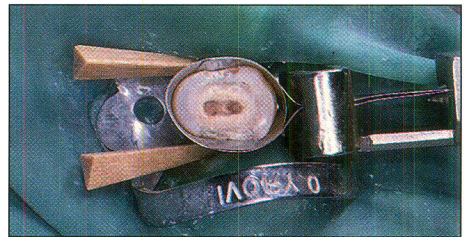
for definitive cast crowns at a later stage when finance was available.

for definitive cast crowns at a later stage when finance was available.

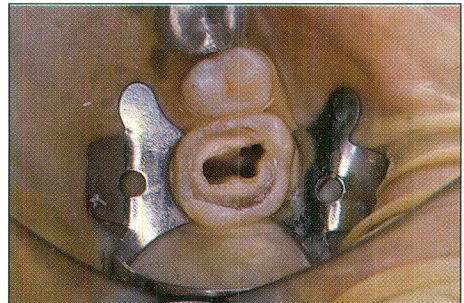
*Figure 2:* Fully prepared root canal system on the 4/ demonstrating the two separate root systems prior to obturation.




*Figure 3:* Placement of matrix band and wedges after successful root canal treatment. The gutta percha has been removed from the first 2-3 mm of the cervical aspect of the root canal system to provide retention for the following amalgam crown.



*Figure 4:* Fully prepared root canal systems on the 6/ demonstrating clearly the four root canal systems commonly found in upper first molar teeth.



*Figure 5:* Placement of matrix band and wedges after successful obturation of the root canal systems. The gutta percha has been removed from the first 2-3 mm of the cervical aspect of each of the root canal systems to provide retention for the following amalgam crown.



*Figure 6:* The initial build-up of the amalgam crown on the 6/. This is carried out with the rubber dam in place after the root canal treatment has been successfully completed and the anatomy of the pulp chamber and the four root canal systems are still fresh in the operators mind.

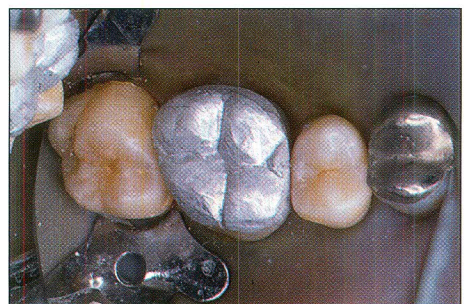



Figure 7: Both amalgam crowns functioning in the mouth after the final occlusal adjustment.

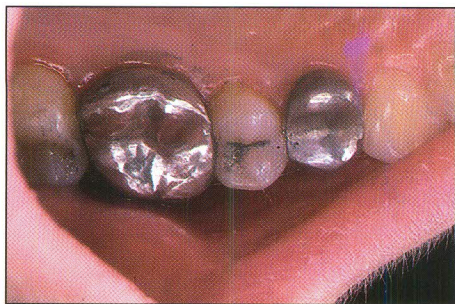
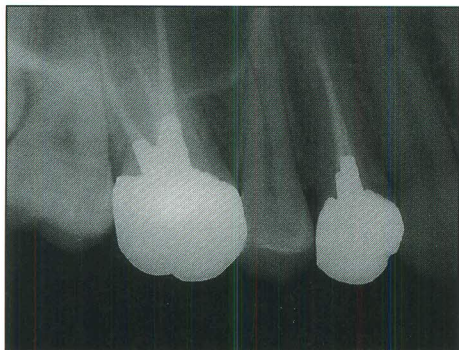


Figure 8: Post operative radiograph confirms the successful obturation of both teeth and the successful obturation of both teeth and the successful build-up of both crowns with amalgam extending into the cervical areas of each of the roots for enhanced retention. These can later be prepared for cast crowns and will function as such as cores for such crowns.



#### REFERENCES

1. Helfer, AR., Melnick, S., Schilder, H.: Determination of the moisture content of vital and pulpless teeth. *J. Oral Surg.* 34: 661, 1972.
2. Radke, RA., Eissmann, HF., Postendodontic Restoration (Chapter 21) in Pathways of the Pulp (Editors S. Cohen and R. Burns) 5th Edition: 640, 1991. CV. Mosby/Mosby Year Book Inc., St. Louis.
3. Johnson, JK., Schwartz, NI., Blackwell, RT., Evaluation and restoration of endodontically treated posterior. *J. Am. Dent Assoc.* 93: 597, 1976.
4. Schillingburg, HT., Fisher, DW., Dewhirst, RB.: Restoration of endodontically treated posterior teeth. *J. Prosth. Dent.*, 24: 401, 1970.
5. Stern, N., Hirshfeld, Z. Principals of preparing endodontically treated teeth and core restorations. *J. Prosth. Dent.*, 30: 162, 1973.
6. Perel, ML, Muroff, FI: Clinical criteria for posts and cores. *J. Prosth. Dent.*, 28: 405, 1972.
7. Schillingburg, HT., Hobo, S., Whitsett, LD., Fundamentals of Fixed Prosthodontics, 2nd Edition. Quintessence Publishing Co., Inc., Chicago, 1981.
8. Smales, RJ., Wedbester, DA., Leppard, PI. Survival predictions of four types of dental restorative materials. *J. Dent.*, 19: 278, 1991.
9. Smales, RJ., Webster, DA.; Leppard, PI., Dawson, AS.: Predictions of amalgam restoration longevity. *J. Dent.*, 19: 18, 1991.
10. Smales, RJ., Webster, DA., Leppard, P.I.: Survival predictions of amalgam restorations. *J. Dent.*, 19: 272, 1991.
11. Sorensen, JA, Martinoff, JT., Intracoronal reinforcement and coronal coverage: A study of endodontically treated teeth. *J. Prosth. Dent.* 1984; 51: 780-84.
12. Liberman, R., Judes, H., Cohen, E., Eli, I: Restoration of posterior pulpless teeth: Amalgam overlay versus cast gold onlay restoration. *J. Prosth. Dent.*, 57: 540, 1987.

13. Gordon, M., Judes, H. Laufer, B., Shifman, A.: An immediate dual-purpose restoration of posterior root filled teeth (the "amalgam crown"). *Dent. Med.*, 2; 22, 1984.
14. Brown, BR., Barkmeier, WW., Anderson, RW: restoration of endodontically treated posterior teeth using amalgam. *J. Prosth Dent.*, 41:40, 1979.
15. Starr, C.B.: Amalgam crown restorations for posterior pulpless teeth. *J. Prosth. Dent.*, 63: 614, 1990.
16. Galindo, Y: Stress induced effects of retentive pins. A review of the literature. *J. Prosth. Dent.*, 44: 183, 1980.
17. Birtcil, RF., Venton, EA: Extracoronal amalgam restorations utilising available tooth structure for retention. *J. Prosth. Dent.*, 35: 171, 1976.
18. Garman, TA., Hawkins, IK, Outhwaite, WC., Douglas Smith, C: A clinical comparison of dentinal slot retention with metallic pin retention. *J. Amer. Dent. Assoc.*, 107: 762, 1983.
19. Fischer, GM., Stewart, GP., Panelli, J.: Amalgam retention using pins, boxes, and amalgabond. *J. Amer. Dent. Assoc.*, 6: 173, 1993.
20. Nayyar, A., Walton, RE., Leonard, LA.: An amalgam coronal radicular dowel and core technique for endodontically treated posterior teeth. *J. Prosth. Dent.*, 43: 511, 1980.
21. Schillingburg, HT., Hobo, S., Whitsett, L. D. Preparations for Extensively Damaged Teeth in Fundamentals of Fixed Prosthodontics, 2nd Edition. Quintessence Publishing Co., Inc., Chicago, p. 157, 1981.

*african*

**L • E • I • S • U • R • E**

**TAILOR MADE HOLIDAYS IN AFRICA**

Talk to anyone who has been to Africa, it is usually a holiday not to be forgotten. Now is the time to visit South Africa while it is still good value and not overrun with tourists.

We advise on and arrange holidays to South Africa, Zimbabwe and Botswana to suit your budget and your particular interest. We have particular expertise in conferences, golfing itineraries and safari trips.

We have an office in Capetown, so you will be well looked after. Now is the time to talk to us as flights and good accommodation are scarce and need to be booked well in advance.

*For further information contact Marie.*

**TEMPLE HOUSE**

Temple Road, Blackrock,  
Co. Dublin.  
Telephone: 2782225. Fax. 278225